

Val d'Isère, 01-2018

How I do a posterolateral corner reconstruction.

Prof. Romain Seil, MD, PhD

Orthopaedic
Surgery



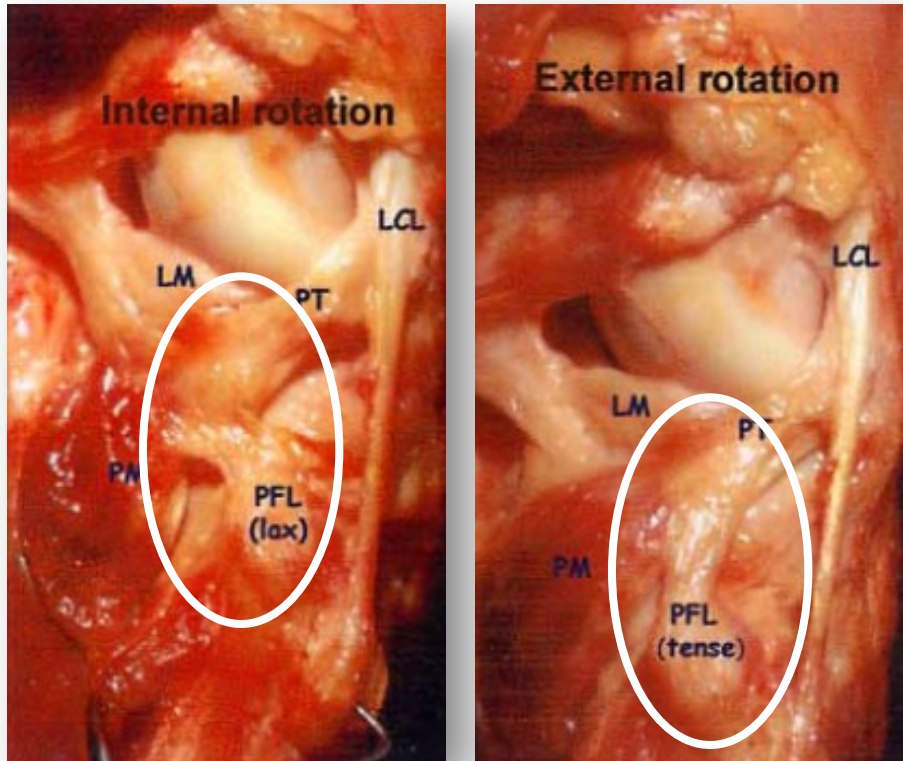
Centre Hospitalier
de Luxembourg

Sports Medicine
Research Laboratory



Luxembourg
Institute of Health

Anatomy & biomechanics

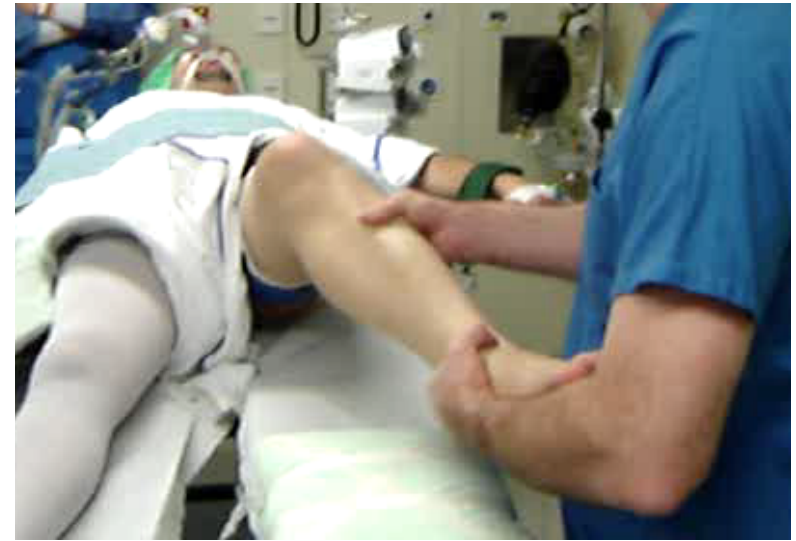
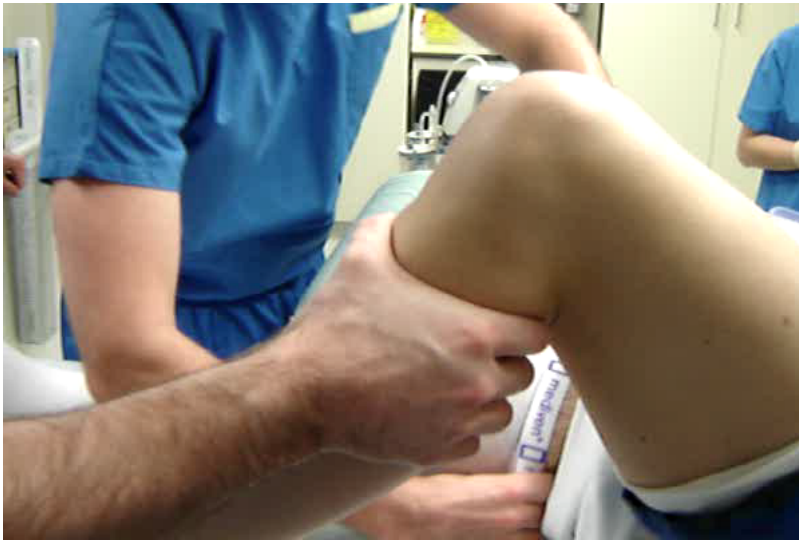
From: Ullrich K, 2002

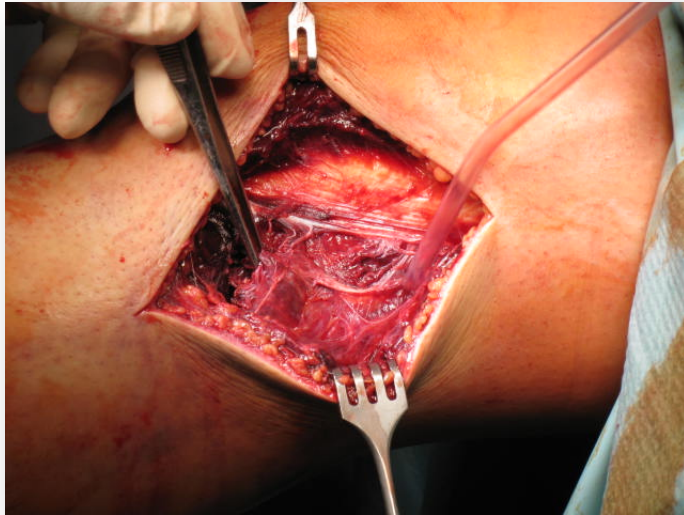
Posterolateral view, right knee

3 main static stabilizers:
PFL
LCL
Popliteus tendon

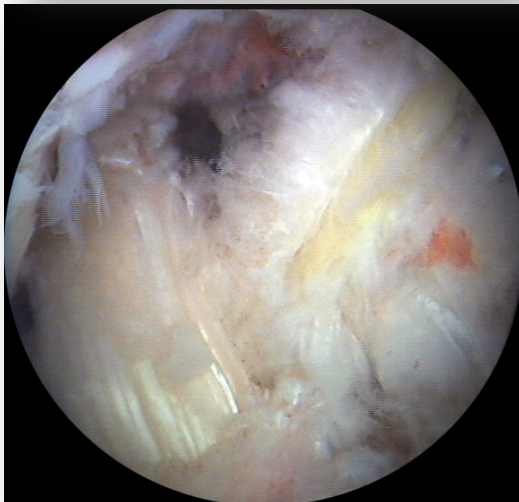
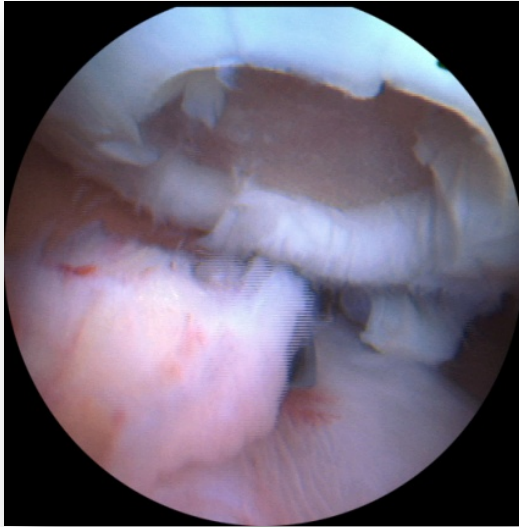
Examination under anesthesia



Ligament reconstruction

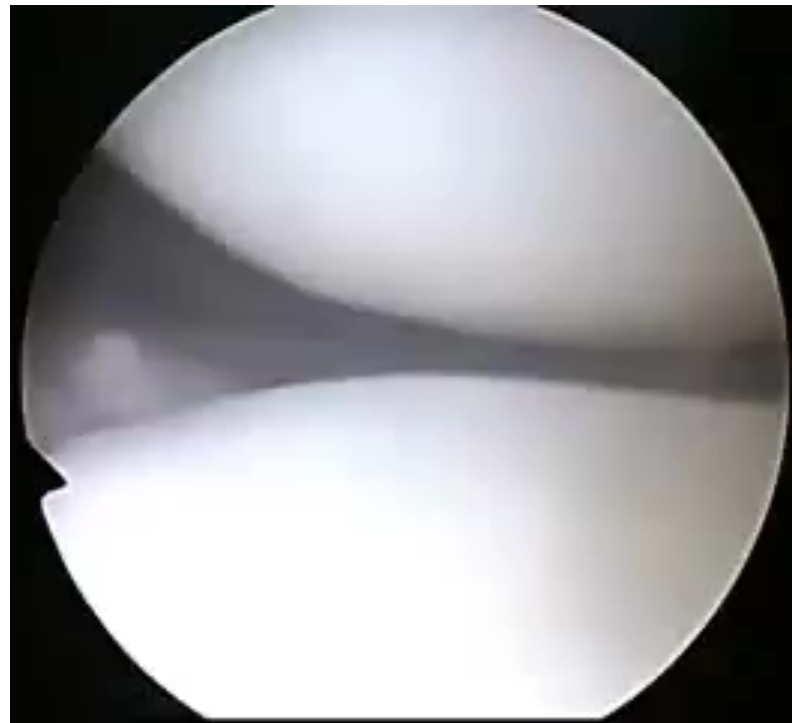
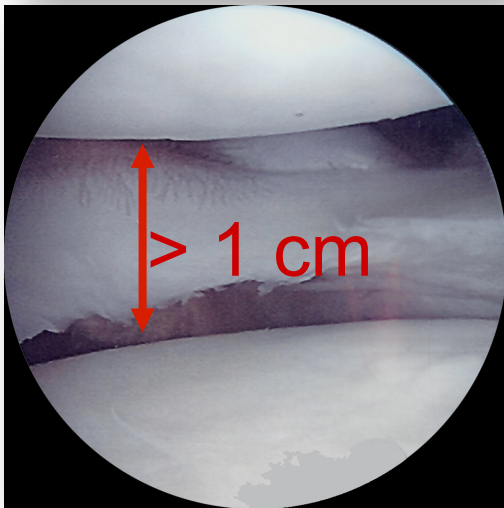
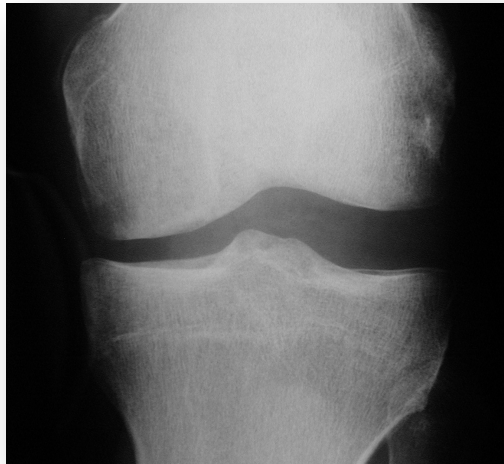

- ✧ Timing: 2-3 weeks !
- ✧ Acute differed surgery
- ✧ Surgery before scar tissue formation & retraction, BUT: enough healing to allow for arthroscopic procedure.
- ✧ ACL/PCL
- ✧ Peripheral structures: repair/reconstruction

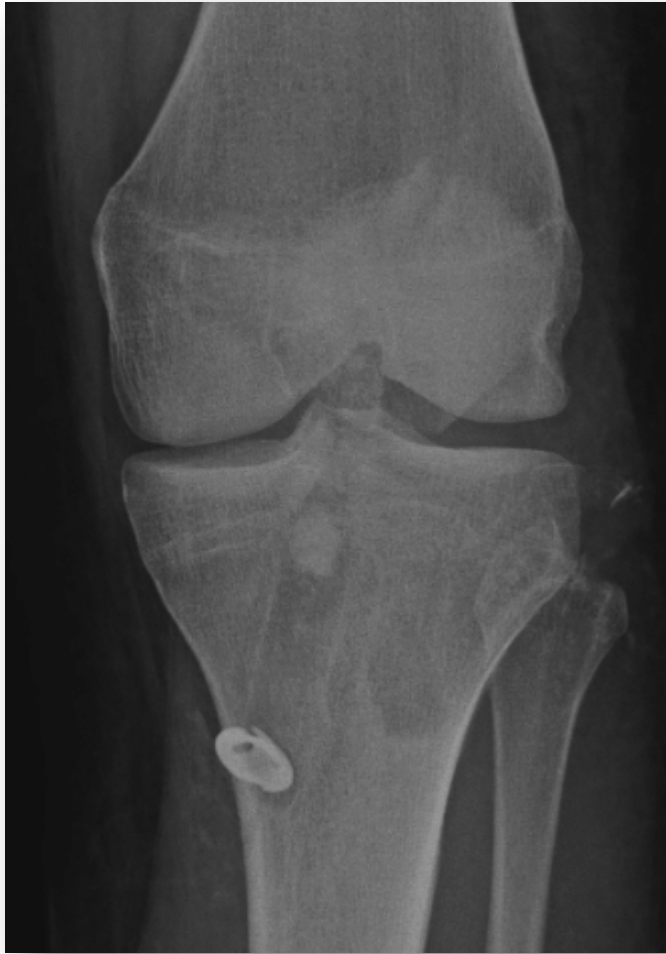

- ✧ Beware fluid extravasation
- ✧ Consider from day 10
- ✧ Confirm diagnosis (popliteus)
- ✧ Cartilage, meniscus surgery
- ✧ ACL/PCL reconstruction

Drive-through sign

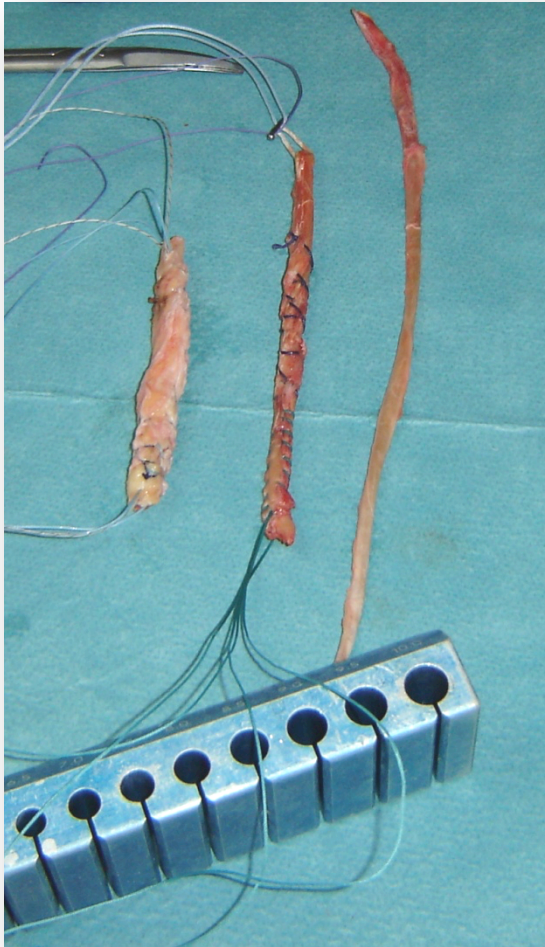


Surgical sequence



Long procedures (tourniquet time)

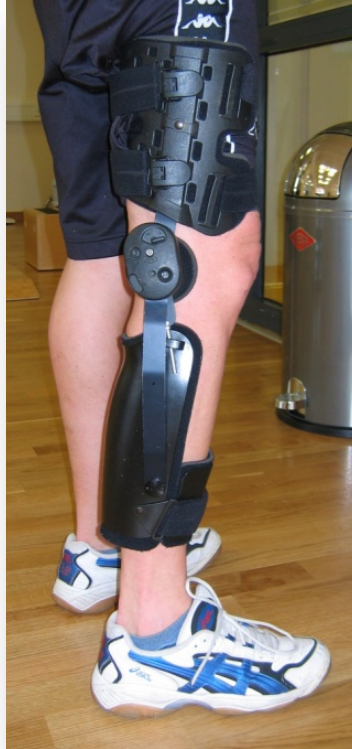- ✧ Tunnel drilling
- ✧ Graft harvesting & preparation
- ✧ ACL/PCL reconstruction (fix PCL first)
- ✧ PLC reconstruction



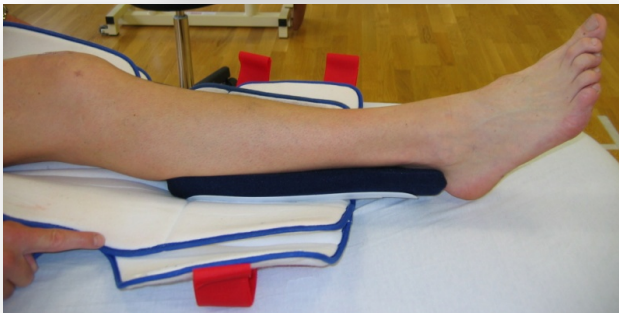- ✧ Patellar tendon
- ✧ Hamstrings
- ✧ Quadriceps
- ✧ Biceps (augmentation)
- ✧ IT band
- ✧ (allografts)
- ✧ consider contralateral side

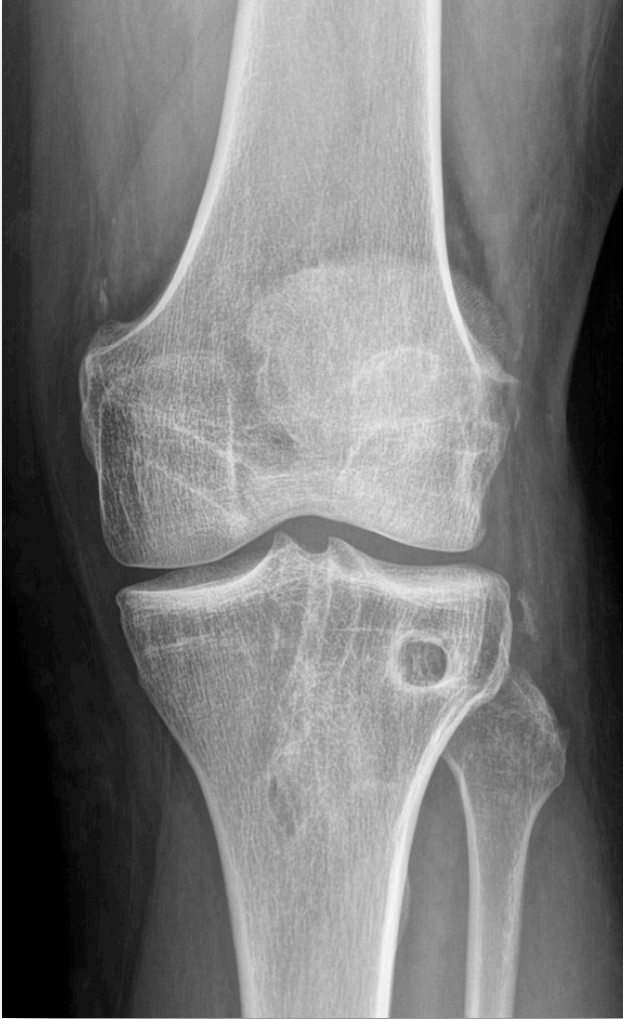

Courtesy of Lars Engebretsen & Rob La Prade



- ✧ Early mobilisation
- ✧ Long functional rehab (9-12 months)
- ✧ PCL: Flexion limited at 60° for 6 weeks
- ✧ Partial weightbearing for 6 weeks
- ✧ Day: JACK PCL (Albrecht)
3 – 6 months
- ✧ Night: PTS brace (Medi/Bayreuth)
3 months





- ✧ Complex lesions – difficult context
- ✧ Often delayed diagnosis
- ✧ Left alone → severe functional impairments
- ✧ Require high-level treatment
- ✧ Difficult surgery
- ✧ Good results in experienced setting

See You in Glasgow

18th ESSKA Congress
9 – 12 May 2018

SECC, Glasgow, Scotland



www.esska-congress.org

www.peoplemakeglasgow.com



PEOPLE
MAKE
GLASGOW